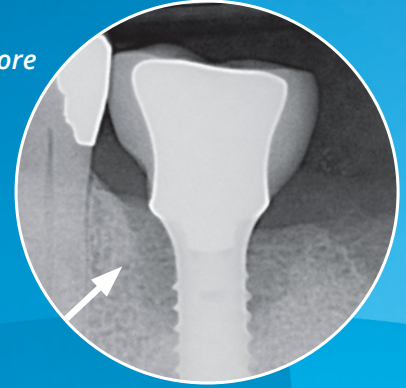



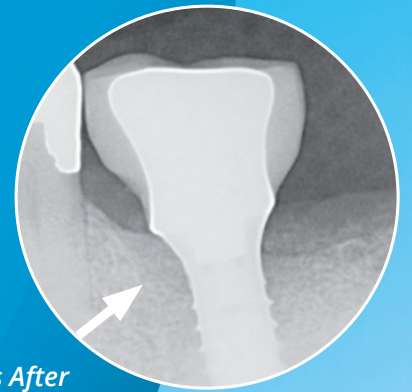
# Manage Ailing & Failing Implants with

 **REPAIR™**

*Before*




*12 Months After*



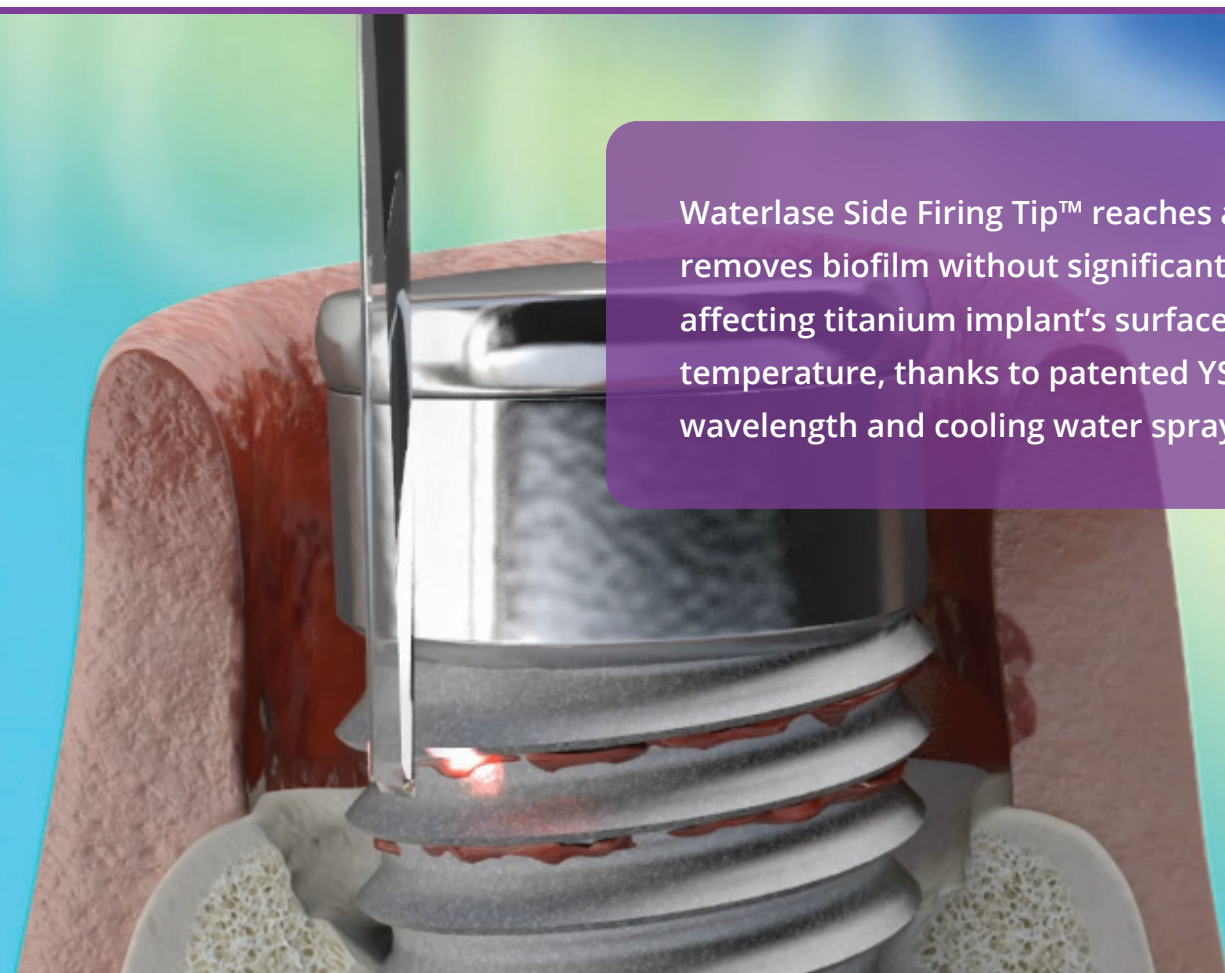
# REPAIR™

## *A Minimally Invasive Protocol for Effective Management of Peri-Implantitis*

As we have all seen, the incidence of peri-implantitis will only continue to increase, with more implants being placed than ever. REPAIR Implant™ provides clinicians a scientifically advanced method to assist in the management of peri-implantitis. This innovative method is a safe, effective laser treatment protocol that patients accept and prefer. Thanks to the unique side firing tip and thin tips, the procedure is minimally invasive, and allows for easy access to the implant surface and in-between threads. Treat site-specific or full-mouth cases for greater flexibility in treatment planning. Waterlase's unique YSGG wavelength makes it the only all tissue laser that can effectively and safely be used to debride titanium implant surfaces without superheating the implant surface and surrounding tissue.<sup>1</sup>



Samuel B. Low, DDS,  
MS, MEd



Waterlase Side Firing Tip™ reaches and removes biofilm without significantly affecting titanium implant's surface temperature, thanks to patented YSGG wavelength and cooling water spray.\*\*\*

# REPAIR™

## WATERLASE® ER,CR:YSGG PERI-IMPLANTITIS REGIMEN

REPAIR Implant is the first definitive step-by-step protocol for using a Waterlase laser to assist in the management of peri-implantitis. It consists of three phases: pre-surgical, surgical and post-surgical.

### PHASE I: PRE-SURGICAL PHASE

All patients should have a comprehensive examination/evaluation including data collection of periodontal charting and radiographs, medical and dental history, and risk assessment. Differentiating between implant mucositis and peri-implantitis is critical in development of procedure choice.

Phase I treatment is implemented for removal of supra- and subgingival biofilm via safe ultrasonic instrumentation or utilization of air medicinal delivery systems, and the initiation and evaluation of oral hygiene compliance. Remove the crown and abutment, when possible, and a healing cap should be placed on the affected implant body. This allows for vertical laser tip access to the implant. Flap reflection is generally necessary for complete access to ensure degranulation, decontamination of the implant surface, and decortication especially in moderate to severe cases.

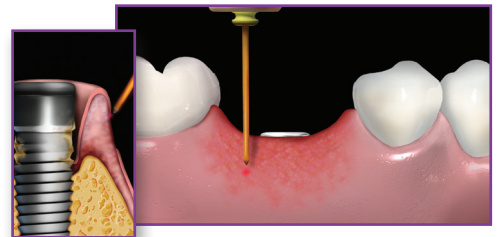
### PHASE II: SURGICAL PHASE

Phase II surgical treatment plan is developed based on the re-evaluation of periodontal inflammation and oral hygiene compliance. The surgical plan can be for a single implant or multiple sites.

#### 1 OUTER DE-EPITHELIALIZATION

Outer pocket gingival epithelium is removed from the free gingival margin down to a width at least equal to the pocket depth.

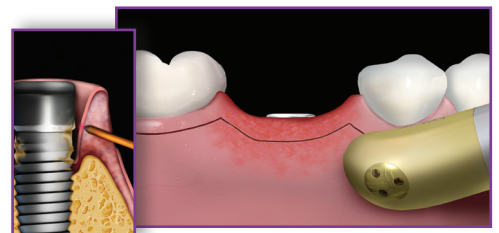
Tip	Power	Air/Water	Pulse rate	Mode
RFPT5	1.5W	40% / 50%	30 Hz	H



#### 2 GINGIVECTOMY (AS NEEDED)

A gingivectomy should only be performed if pseudo-pocketing is present. Ensure you do not compromise adequate attached gingivae.

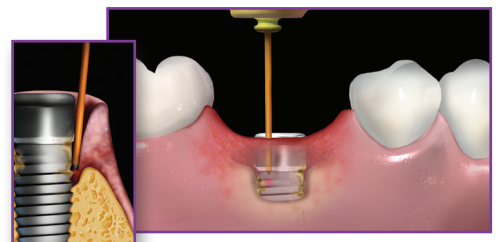
Tip	Power	Air/Water	Pulse rate	Mode
RFPT5	1.5W	40% / 50%	30 Hz	H



#### 3 POCKET DEBRIDEMENT

The epithelium should be removed and should be completed apically, from the free gingival margin down to the osseous level. All granulation tissue is removed. Gingival margin can be reflected as a flap for access.

Tip	Power	Air/Water	Pulse rate	Mode
RFPT5	1.5W	40% / 50%	50 Hz	H



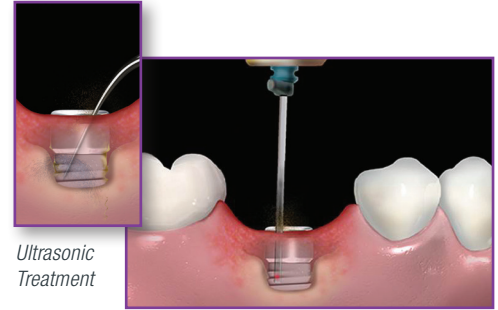


## 4 **IMPLANT DECONTAMINATION**

Conventional treatment with ultrasonics with only implant-safe tips to osseous levels. Please consult your implant manufacturer for recommended ultrasonic tips.) Upon completion, place a side firing tip circumferentially beginning at the coronal surface of the first thread exposed and move apically to most apical osseous levels. Air medicinal delivery systems can be utilized at this juncture.

NOTE: When using the side firing tip, the orientation of the tip handle should be opposite (180°) the direction of the laser energy output.

Tip	Power	Air/Water	Pulse rate	Mode
SFT8	1.5W	40% / 50%	30 Hz	H



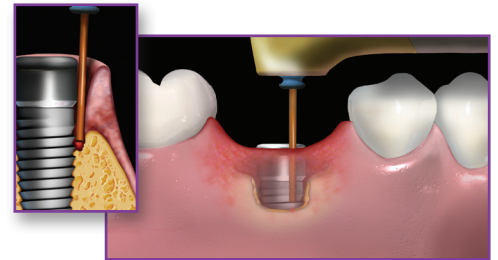
Ultrasonic Treatment

Side-Firing Tip

## 5 **DECORTICATION**

Re-contour osseous defects including decortication to stimulate bone regeneration. Hold tip parallel to implant surface and gently tap all the way down to and into bone, retracting slightly and repeating all the way around the implant. If necessary, change angle of laser tip and treat into the walls of infrabony defects. Depending on osseous topography, the clinician can now consider the use of osseous augmentation and/or biologics for regeneration.

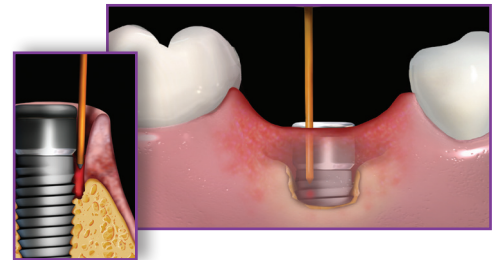
Tip	Power	Air/Water	Pulse rate	Mode
MZ6	2.4W	70% / 80%	30 Hz	H



## 6 **FINAL DEBRIDEMENT**

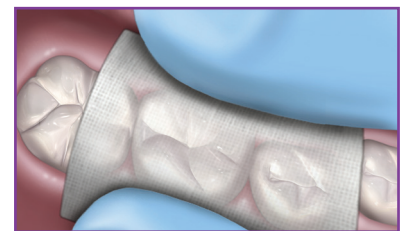
Remove residual debris and induce blood coagulation if one elects not to use regenerative materials.

Tip	Power	Air/Water	Pulse rate	Mode
RFPT5	1.5W	10% / 10%	50 Hz	H



## 7 **COMPRESS WITH 2X2 GAUZE**

Compress surgical site with wet 2x2 gauze for 2 minutes. Maintain flap adaptation with either suture or cyanoacrylate.

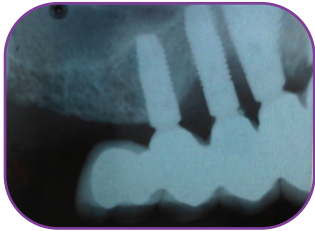


### PHASE III: POST-SURGICAL PHASE

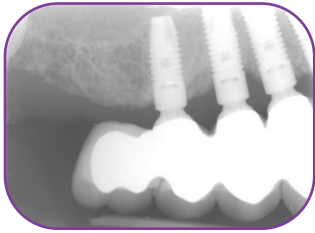
- Immediate post-operative: Brush teeth lightly with soft brush and use oral rinse to supplement brushing if discomfort exists. Utilize appropriate analgesics.
- One week after laser treatment: Gently clean between teeth using an interproximal brush dipped in appropriate oral rinse.
- No probing for at least 3 months, at which time a supragingival debridement is completed.

# REAL RESULTS

**CASE 1** – Courtesy of Dr. Rana Al-Falaki

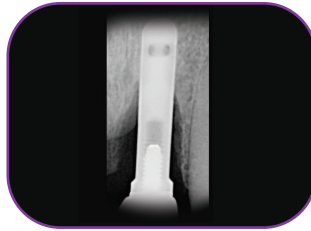


BEFORE




12 MONTHS AFTER FLAPLESS TECHNIQUE

**CASE 2** – Courtesy of Dr. Paul Chang

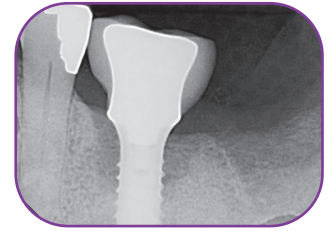


BEFORE

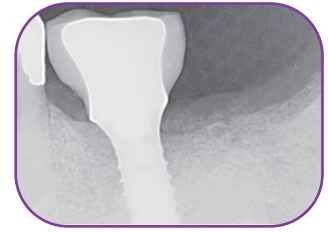


12 MONTHS AFTER

**CASE 3** – Courtesy of Dr. Todd Jorgenson



BEFORE



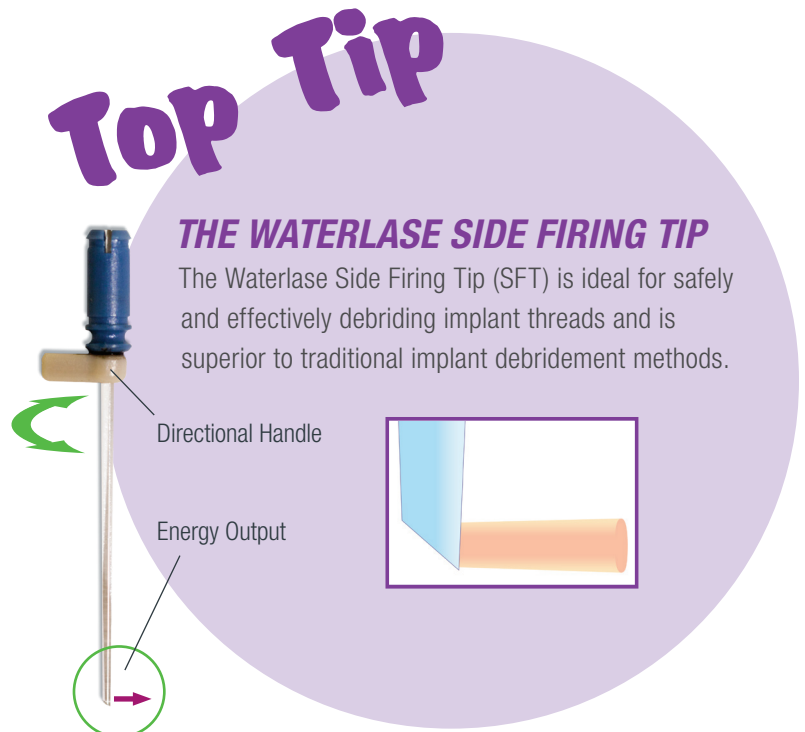
12 MONTHS AFTER

## BACKED BY LANDMARK SCIENTIFIC RESEARCH

Data in the International Journal of Periodontics & Restorative Dentistry demonstrates the value of laser technology in treating peri-implantitis.

The study published in the International Journal of Periodontics & Restorative Dentistry highlights the value of Er,Cr:YSGG lasers for the debridement of titanium implants. In this study, a laser treatment was carried out at a setting of 1.5 W, air/water of 40%/50%, and pulse rate of 30 Hz.

Patients who received the treatment returned with positive clinical outcomes. In simple terms, this study emphasizes the positive role that dental lasers can play in decontaminating surfaces surrounding implants, where elements including biofilm can contribute to peri-implantitis.



# WORLD-CLASS EDUCATION



## TRAINING:

- ✦ Beginning your laser journey? Seminars teach a broad overview of laser benefits
- ✦ Choose Waterlase Foundations or our Advanced Series- 5 highly focused specialist courses
- ✦ Want a one-on-one mentorship? On-Demand in-person training with content tailored to your practice.

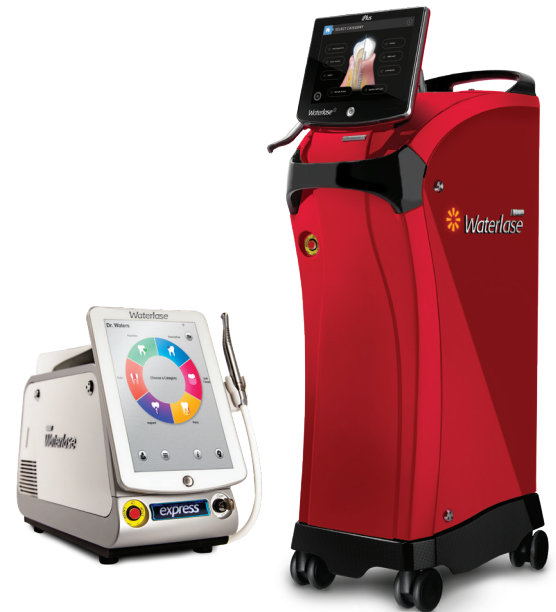## FREE RESOURCES:

- ✦ Live, free CE webinars monthly featuring the best in laser dentistry
- ✦ Library with 100+ hours of free on-demand webinars
- ✦ Join thousands of clinicians to connect and share knowledge in the Waterlase Dentist Facebook group
- ✦ Clinical animation guides, protocol guides, clinical gallery

Visit [Education.biolase.com](https://www.education.biolase.com) for more information.

# INNOVATIVE TECHNOLOGY

- ✓ Waterlase's proprietary YSGG wavelength is effective in **removing surface contamination** and facilitating subsequent **regenerative treatment**<sup>1</sup>
- ✓ **Bone to implant contact** can be reestablished on a previously contaminated implant surface following REPAIR Protocol<sup>1\*</sup>
- ✓ **Tissue regeneration can be achieved** using Waterlase®, as confirmed by human histology<sup>1</sup>



Visit [biolase.com/implantitis](https://www.biolase.com/implantitis)

<sup>1</sup> Human Histologic Evaluations of the Use of Er,Cr:YSGG Laser to Decontaminate an Infected Dental Implant Surface in Preparation for Implant Reosseointegration; Myron Nevins, Stefano Parma Benfenati, Primo Galletti, et. al.; International Journal of Periodontics and Restorative Dentistry, November/December 2020, Volume 40, Issue 6. \*Freeze-dried bone allograft, recombinant human platelet-derived growth factor-BB, and collagen barrier membrane were used to graft the defect in addition to laser detoxification.



**BIOLASE**  
LEADER IN DENTAL LASERS™

©2023 BIOLASE, Inc. All rights reserved. 21-1992

For more information, visit [biolase.com](https://www.biolase.com)

